

# Cataract surgery: from less drops to drop less.

Current concepts in antibiotic prophylaxis

David Markoff, MD, FACS

Mountain Eye Associates PLLC

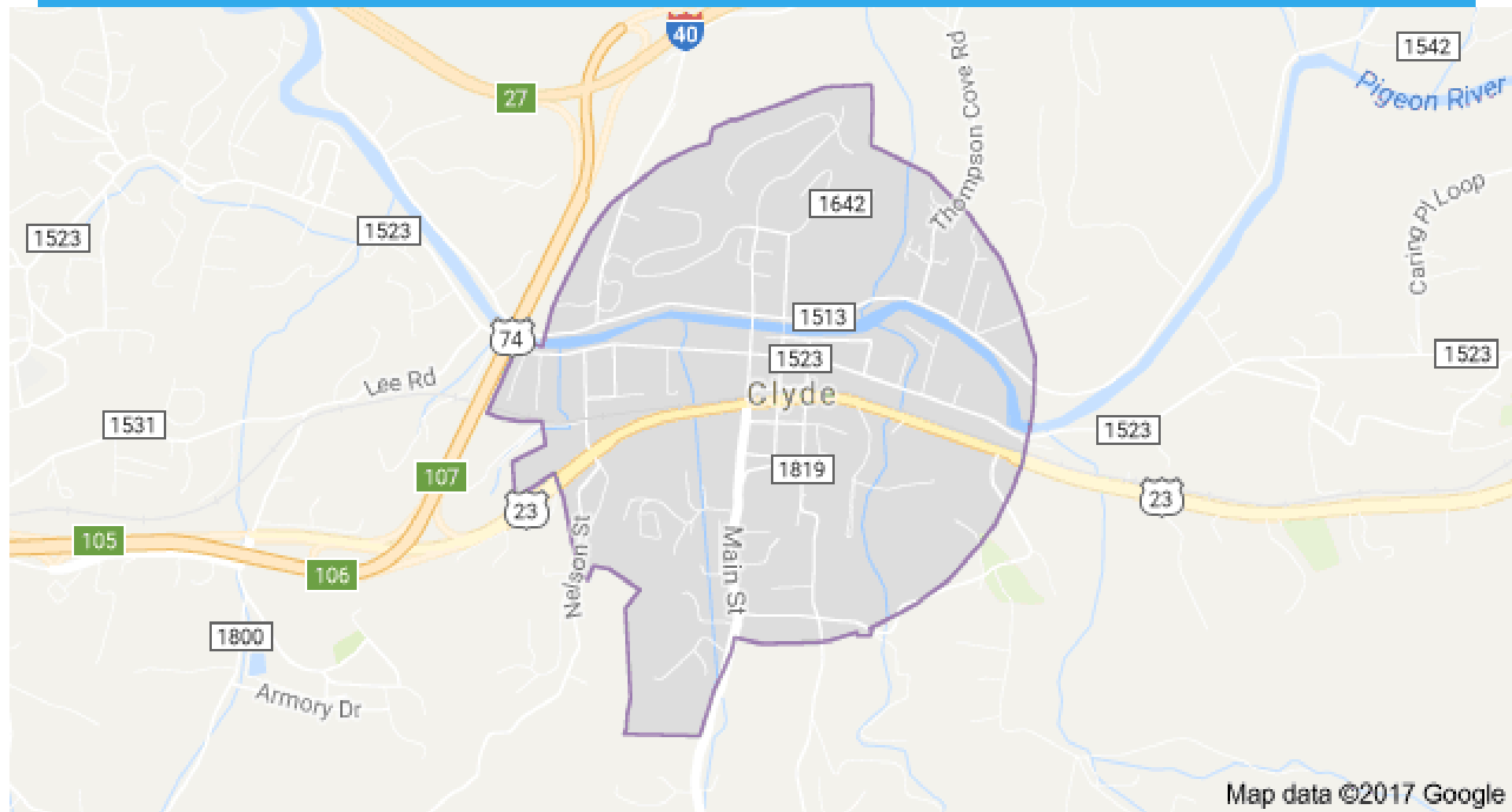Haywood Regional Medical Center

Clyde, NC



- \* Financial Disclosures

- \* None



Map data ©2017 Google

# The obvious

- \* Endophthalmitis is a very undesirable outcome after cataract surgery for both clinical and medicolegal reasons

# The Incentive

- \* Using the 4<sup>th</sup> generation flouoroquinolones (specifically vigamox) topcially before and after surgery I had not had an endophthalmitis case in over a decade
- \* However, more and more patients were complaining about the high cost of the drops (\$200-300) and patients have never liked the frequent administration schedule

# Our previous long term practice

- \* Vigamox qid starting 3 days preop and continuing 7-10 days post op
- \* Post op steroid qid for 1<sup>st</sup> week and then tapered
- \* NSAID

# Endophthalmitis Prophylaxis

- \* What do we really know? Not much.
- \* Standard of care different in different parts of the world
- \* Personal “comfort” with frequent drop administration- we feel like we are doing something
- \* Recent European, US, and Indian data

# Beautiful Betadine

- \* The authors conducted an open-label nonrandomized parallel trial to examine whether the preoperative application of povidone-iodine to the ocular surface reduces the incidence of endophthalmitis after intraocular surgery. During an 11-month period, topical 5% povidone-iodine was used to prepare the conjunctiva in 1 set of 5 operating rooms, while silver protein solution was used in another set of 5 rooms. In all cases, surgeons continued to use their customary prophylactic antibiotics. A significantly lower incidence of culture-positive endophthalmitis ( $P < 0.03$ ) was observed in the operating rooms using povidone iodine (2 of 3489 or 0.06%) compared with those using silver protein solution (11 of 4594 or 0.24%). Use of topical povidone-iodine in over 3000 cases was not associated with any adverse reactions. In a majority of the observed cases of endophthalmitis, some form of intraoperative communication with the vitreous cavity existed.
- \* Speaker, Menikoff Ophthalmology December 1991



# ESCRS study Group Report

## JCRS June 2007

- \* 2X2 study, IC cefuroxime and topical levofloxacin
- \* 1mg/.1cc cefuroxime
- \* Levo 2 drops in hour before surgery, 3 drops soon post-op
- \* All patients used levofloxacin qid for 6 days post-op
- \* All patients had betadine prep

# ESCRS study Group Report

## JCRS June 2007

- \* About 4000 pts per arm of study
- \* Group A, no periop drops, no IC cefuroxime, endophthalmitis rate .345%
- \* Group B no drops but IC .074%
- \* Group C drops but no IC .247%
- \* Group D drops and IC .049%
- \* Small numbers so confidence intervals overlapped but definite trends

# ESCRS study Group Report

## JCRS June 2007

- \* No IC cefuroxime RR 4.92
- \* Clear cornea vs scleral tunnel 5.88
- \* Silicone vs Acrylic IOL 3.13
- \* Surgical complications 4.95

# Kaiser Study

## Shorstein, Winthrop, Herrinton

### JCRS January 2013

- \* Looked at >16,000 cases from 2007-2011
- \* Divided into 3 time periods
  - \* Drops only
  - \* IC cefuroxime in non PCN allergic and no PCR cases
  - \* IC on all patients (cefuroxime>moxi>vanco)
  - \* Also looked at subset of surgeons in 3<sup>rd</sup> time period who used only IC without postop drops

# Kaiser Study

Shorstein, Winthrop, Herrinton  
JCRS January 2013

- \* Enophthalmitis rates per 1000 were .313%, .143%, .014%
- \* Change in rate appeared to be due to instituting 100% IC administration rather than to change in topical therapy (tobramycin to gatifloxacin)
- \* In 2038 surgeries with IC but no topical .049% rate which was only 1 case

# Kaiser Study

Shorstein, Winthrop, Herrinton  
JCRS January 2013

- \* Endophthalmitis cases in patients who received IC antibiotics tended to be milder with better final visual acuity
- \* “Intracameral injection alone, without additional perioperative antibiotic drops, may be highly protective against endophthalmitis.”

# Aravind Study

Haripriya, Chang, Ravindran  
Ophthalmology June 2017

- \* 617,453 surgeries Jan 2014-May 2016 at 10 Aravind Eye Hospitals
- \* Retrospective based on standardized clinical registry
- \* 302,815 eyes no IC Moxi, 314,638 with IC Moxi
- \* All eyes topical ofloxacin every 3 hours 1 day preop and twice the AM of surgery and then tid for 15 days post op.
- \* Betadine on eye with lid prep in OR

# Aravind Study

- \* Additionally, topical combo gati/dex used 8X/day for first week and then tapered over 4-6 weeks.
- \* So, extensive topical prophylaxis
- \* For IC administration, 0.1ml of 0.5% moxi placed at end of surgery



# Aravind Study

\* 194,252 phaco eyes. Endophthalmitis rate 0.07% to 0.01% with IC moxi.

414,657 M-SICS eyes rate 0.07% to 0.02%.

Overall endophthalmitis rate 0.07% to 0.02%

# Aravind Study

- \* 8479 eyes with intraop PC rupture (1.37%)
- \* ½ with IC moxi, and ½ without
- \* Without IC moxi endophthalmitis rate 0.48%
- \* With IC moxi endophthalmitis rate 0.21% (still 10X the rate without PC rupture)

# Aravind Study

- \* 3.5 fold reduction in endophthalmitis
- \* 3 fold for M-SICS and 6 fold for phaco
- \* Beneficial for eyes with Intraop PCR

# Aravind Study

- \* “Considering the association of hemorrhagic occlusive retinal vasculitis with vancomycin and the commercial unavailability of IC cefuroxime in many countries, moxifloxacin appears to be an effective option for surgeons electing IC antibiotic prophylaxis”

# In Vitro Study

- \* Endophthalmitis prophylaxis by intracameral antibiotics: In vitro model comparing vancomycin, cefuroxime, and moxifloxacin.
- \* Peter E. Libre, MD, Sean Mathews
- \* JCRS June 2017

# In Vitro Study

- \* “In this pharmacokinetic model of intracameral antibiotics and their effects on endophthalmitis bacteria, moxifloxacin was as effective as vancomycin or cefuroxime against staphylococci, streptococci, and propionibacteria and was more effective against pseudomonads.”

# In Vitro Study

- \* “Moxifloxacin, dosed at highest reported intracameral levels (0.5 mg), was the only single antibiotic effective against all bacterial isolates tested in this study. Effective treatment of pseudomonads required moxifloxacin (high dose alone or low dose combined with cefuroxime).”

- \* Concerns with cefuroxime-endophthalmitis cases which do occur can be from resistant gram negatives (*Enterobacter* sp.) with very poor outcomes, whereas endophthalmitis cases treated with moxifloxacin tend to be gram positives with much better outcomes after treatment



# Arshinoff study

- \* Dose and administration of intracameral moxifloxacin for prophylaxis of postoperative endophthalmitis
- \* Arshinoff and Modabber, JCRS December 2016

# Arshinoff study

- \* Looked at theoretical concentrations of moxifloxacin in the AC after surgery
- \* Assumed fluid volume of 0.5 CC (0.25+.06+.21-IOL volume)
- \* >300ug dose provided >10X MIC 90 of most resistant case reported for at least one hour, and > MIC 90 for 2-3 hours

# Arshinoff study

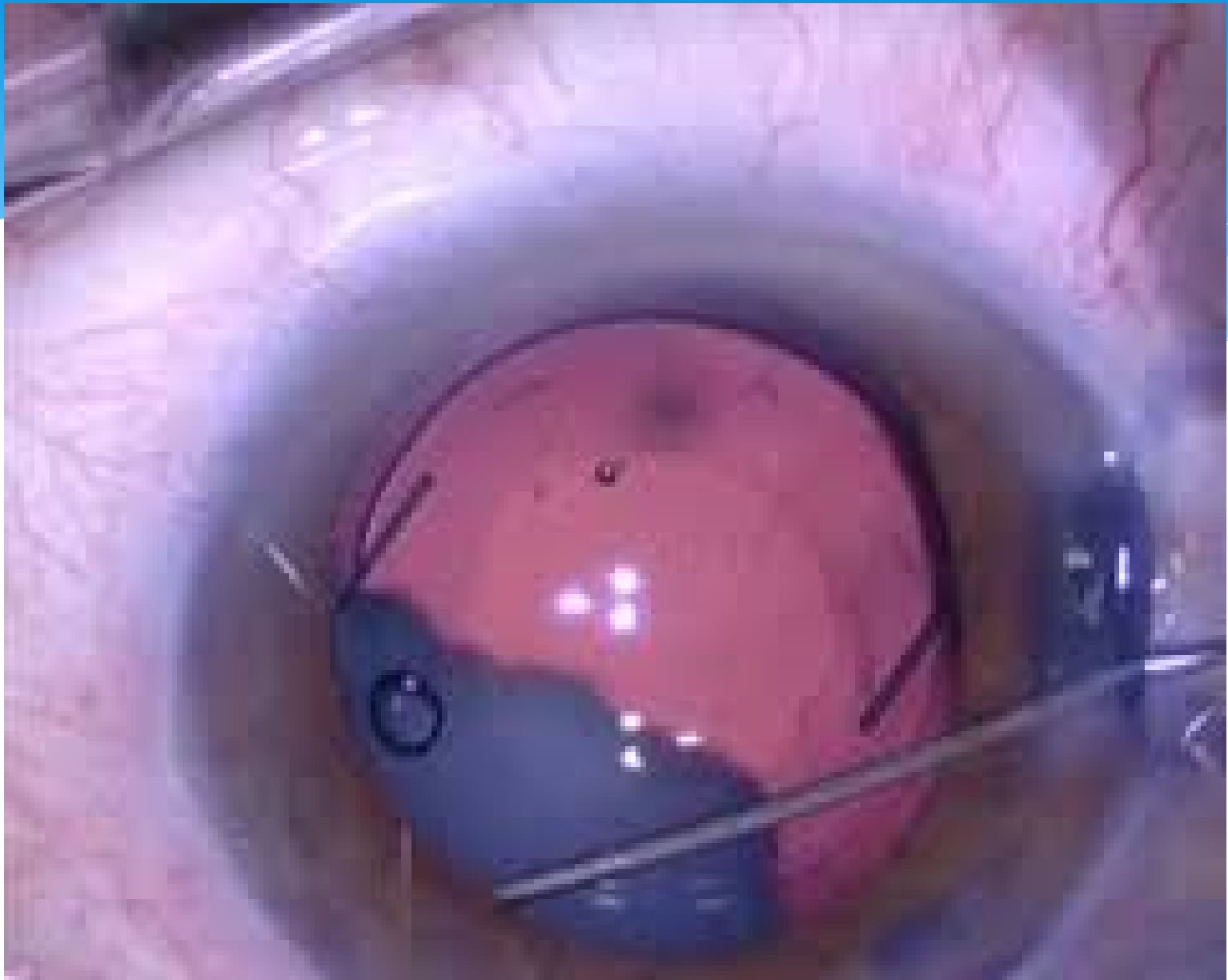
- \* Review of different methods and drugs for intracameral endophthalmitis prophylaxis
- \* His current protocol utilizes intracameral moxifloxacin (Vigamox) mixed to 150ug/0.1ml by diluting a 3cc bottle of Vigamox to 10cc total with BSS

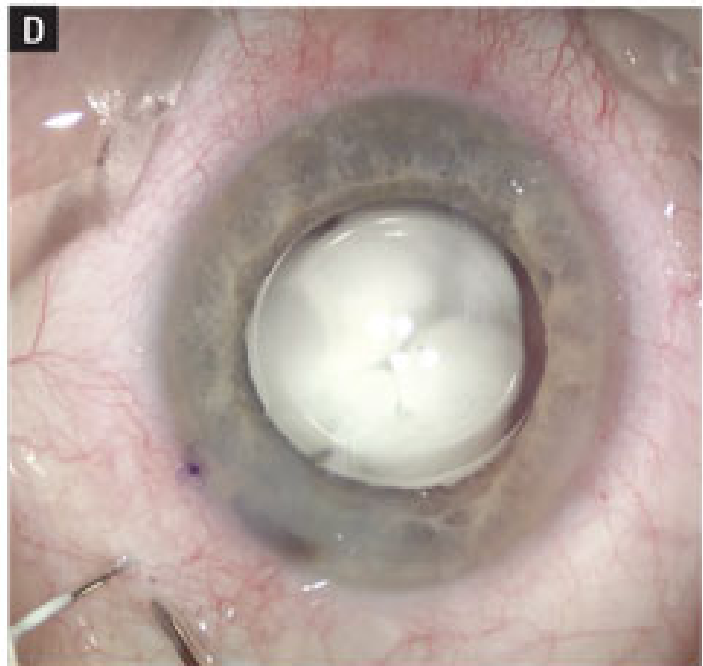
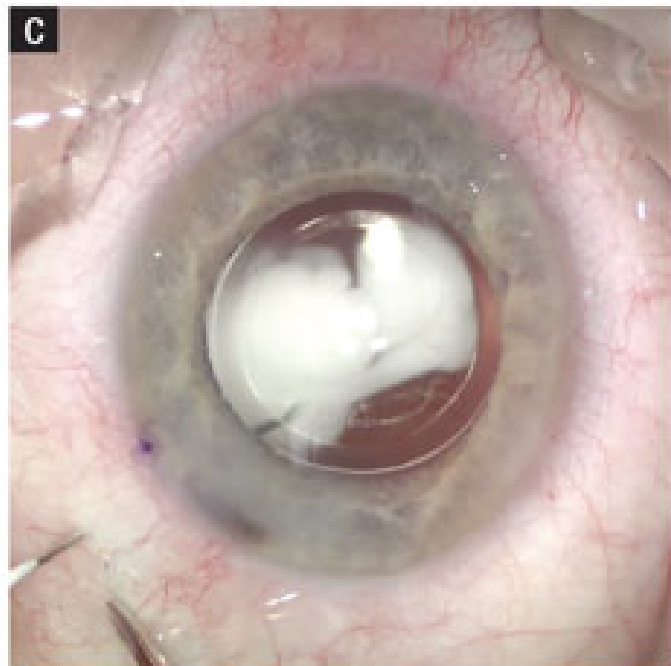
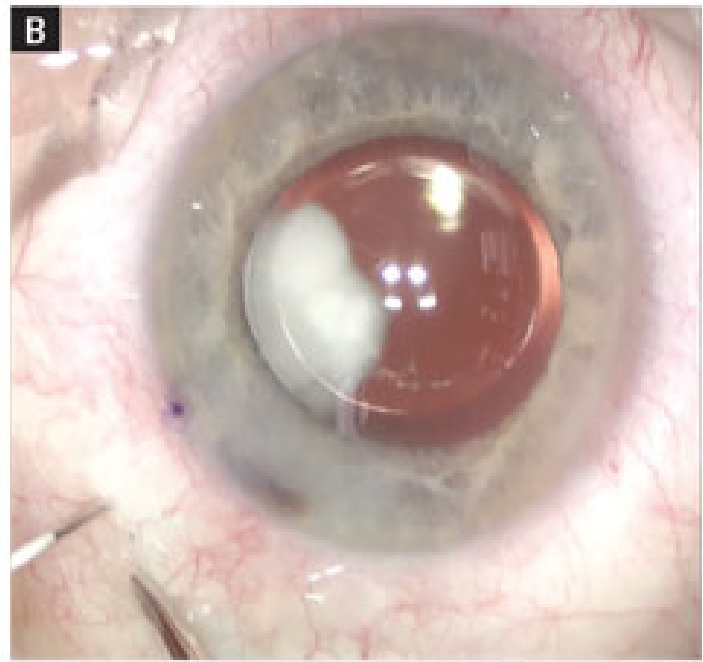
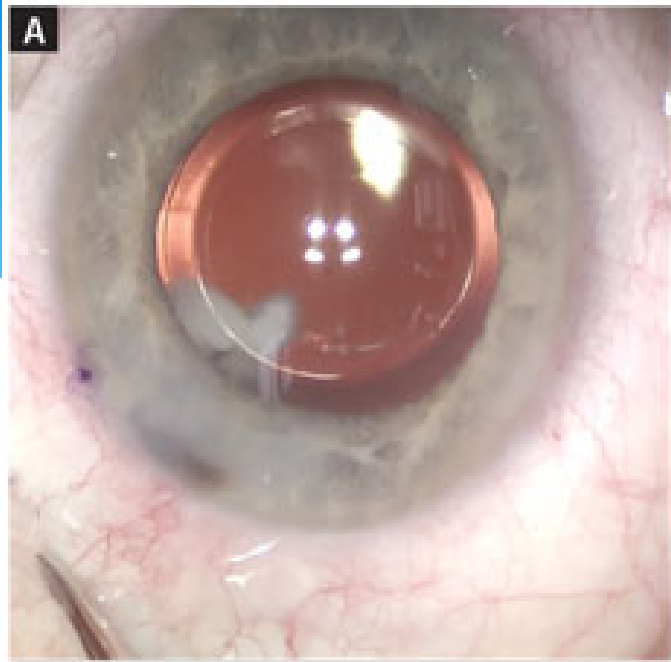
# Arshinoff study

- \* They use easy to remember dilution of 3cc bottle of Vigamox with 7cc of BSS for 10cc of a 150ug/.1ml solution.
- \* Temporal incision is stromally hydrated with BSS
- \* Dilute vigamox, at least 0.3-0.4cc (450-600ug) is then placed in to AC and used to hydrate paracentesis
- \* 1 case of endophthalmitis due to resistant Staph epi in >3000 cases placing just 100ug in AC, none in >4000 cases since using new dosing

# Other methods of intraocular delivery

- \* Intravitreal (transzonular or pars plana)





# CONCERNS

Why disturb zonules you spent your surgery trying to preserve

Pars plana approach not as intuitive to most cataract surgeons as anterior chamber approach

Blurred vision for patient

Difficulty in removal of steroid if large IOP spike

? If antibiotic in vitreous as effective post op as in anterior and posterior chambers

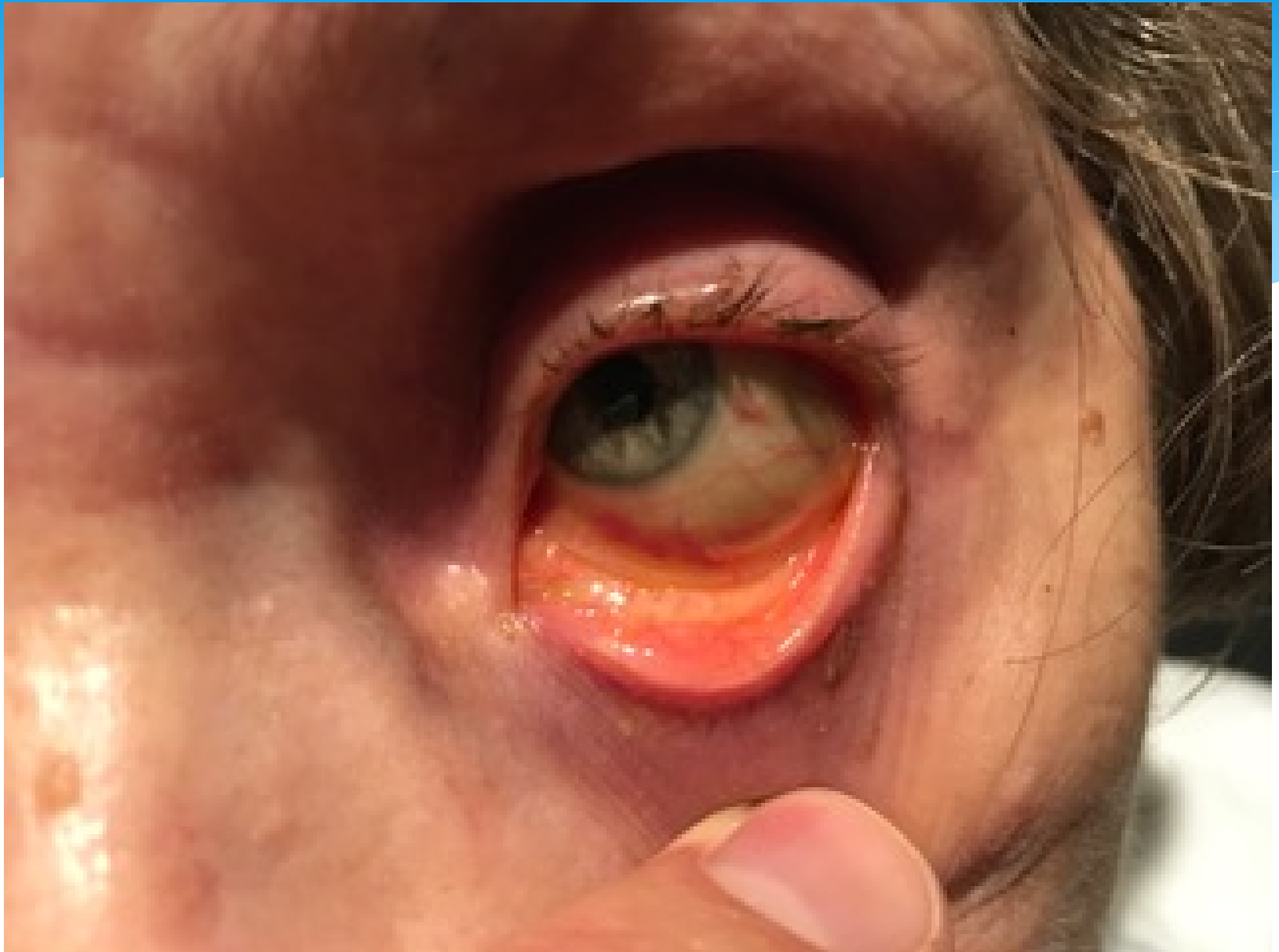

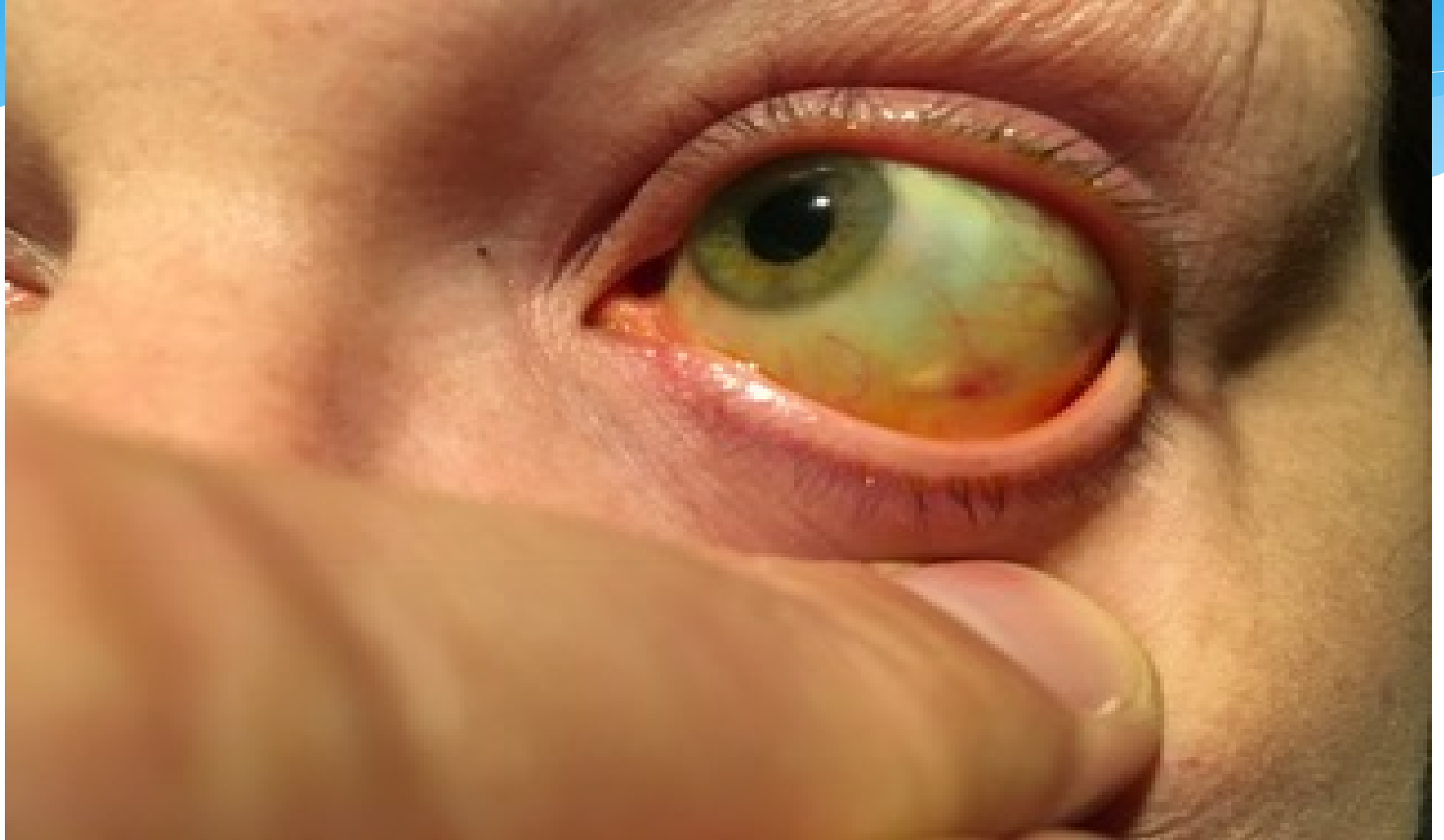# Current Protocol

- \* Drop of Pred-Gati-Nepaf before leaving home and on arrival to the ASC
- \* 5% Betadine in Preop and with eyelid prep
- \* Topical dilating drop mixture
- \* 2.5% betadine immediately post op followed by “dollop” of viscoelastic
- \* 1 drop of Pred-Gati-Nepaf daily for 2 weeks (\$35 through office) can be increased if needed for inflammation, wound leak, etc

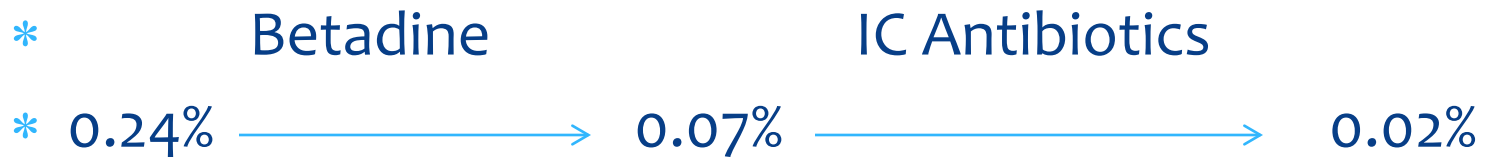# Current Protocol

- \* Pharmacy mixes 3cc moxi bottle (Vigamox) with 12cc BSS for 15cc of a 100ug/.1ml moxi solution.
- \* Depending on the status of the eye at the end of surgery (soft, firm, AC depth etc) I will either replace the AC fluid with moxi and also stromally hydrate both wounds with it, or use BSS to first stromally hydrate the temporal incision and then use moxi to replace the AC and hydrate the paracentesis.
- \* .2cc of 10mg/ml triamcinolone then injected subconj





# Progress



# Concerns

- \* Adequate and consistent IC dosing
- \* Resistance, especially with once daily drops
- \* Dilution and mixing errors- one bad batch = a lifetime of endophthalmitis (recent TX cases)
- \* Would be very nice to have commercially available 150ug/.1cc moxifloxacin solution reasonably priced
- \* Possible use of new generic moxi's may be able to lower costs even further

# Concerns

- \* Many of same concerns applied to IOL's in the early days, but the profession pushed forward, to our patients benefit. Hopefully the same thing will happen with endophthalmitis prophylaxis.

# THANK YOU

- \* [dmarkoff@hushmail.com](mailto:dmarkoff@hushmail.com)
- \* [mountaineyeassociates.com](http://mountaineyeassociates.com)